Cloud Publications
International Journal of Advanced Ayurveda, Yoga, Unani, Siddha and Homeopathy
2026, Volume 15, Issue 1, pp. 943-949
ISSN: 2320–0251

Case Report

Role of Individualized Homoeopathic Treatment for Resolving Atopic Dermatitis: A Case Report

[1]Alok Ranjan, [2]Madina Ansari

[1]Department of Pathology, R.B.T.S Govt. H.M.C & Hospital, Muzaffarpur, Bihar
[2]Department of Homoeopathic Pharmacy, R.B.T.S. Govt. H.M.C & Hospital, Muzaffarpur, Bihar

Correspondence should be addressed Dr. Madina Ansari, PG Scholar, *madinaansari796@gmail.com*

Publication Date: 22 July, 2026

Copyright © 2026 Dr. Alok Ranjan, Dr. Madina Ansari. This is an open access article distributed under the **Creative Commons Attribution License**, which permits unrestricted use, distribution, and reproduction in any medium, provided the original work is properly cited.

Abstract Atopic dermatitis is a chronic, pruritic skin disorder that affects approximately 20–25% of children, with nearly 35% of cases persisting into adulthood. It is widely prevalent in both developing and developed countries and is commonly associated with individuals who have a predisposition to allergic conditions.

The purpose of this case report is to highlight a case of atopic dermatitis associated with psychological symptoms and to demonstrate the effectiveness of individualized homeopathic treatment based on mental, general, and particular symptoms.

A 35-year-old female patient, diagnosed with atopic dermatitis, presented with eczematous lesions over the neck and hands. The lesions were accompanied by burning sensation, redness, and intense itching. The symptoms were aggravated during nighttime and were temporarily relieved by scratching. The patient had previously used conventional dermatological medications, which provided only temporary and partial relief.

Seeking a long-term solution, the patient opted for homeopathic treatment. A detailed case-taking was conducted, followed by analysis using Materia Medica and repertorization. Based on the totality of symptoms, Mercurius solubilis (Merc sol) 30C was prescribed.

Following treatment, the patient showed marked improvement in all symptoms. The intensity of itching and burning reduced significantly, and the eczematous lesions gradually subsided.

This case suggests that individualized homeopathic treatment, particularly with Merc sol, may be beneficial in managing atopic dermatitis when prescribed according to the totality of symptoms. However, further clinical studies are required to validate its effectiveness and establish broader applicability.

Keywords *Atopic dermatitis; individualized homoeoepathic treatment; case report; repertorisation*

Introduction

Atopic dermatitis called as atopic eczema. It is a chronic inflammatory dermal condition related with epithelial, immune and ecological factors. Atopy is characterized as an inherited inclination to produce IgE (immunoglobulin E) antibodies because of moment measures of regular natural proteins such as pollen, dust vermin and food allergens. Dermatitis gets from the Greek “derma” which means skin and “itis” which implies inflammation. The confusion brings in significant morbidity and unfavourable affects nature of life. Not just patients are influenced by the social disgrace of an obvious skin condition, but the extreme itching characteristic of the disease frequently prompts to skin injury and significant rest disturbances. Atrophic generally begins during childhood with a ceaseless dispatching, backsliding course the aliment can endure into adulthood in around one fifth of patients.

Homeopathic writing review uncovered a case analysis done on atopic dermatitis and burdensome issue on a multiyear old male patient through Graphites 1M. The state of patient was steady following a half year and follow up of the patient for next one year with no repeat of skin symptoms. Homeopathy is a treatment dependent on 'like cures like' rule. Homeopaths generally utilized profoundly weakened cures so as to invigorate one mending properties of bodies. Thus, homeopathy is a comprehensive methodology utilized for some, if not most, ceaseless conditions including Atrophic dermatitis.

Three distinct patterns of atopic dermatitis have been recognized, depending on the age of the patient.

Infantile phase	Childhood phase	Adult phase
Begins after the age of 3 months. ❖Intensely itchy papules and vesicles, which soon become exudative. ❖Begins on the face but can involve rest of the body, but sparing the diaper area. ❖Secondary infection common. ❖Runs a chronic course: ✓ In 40% infants, lesion clears by the age of 18 months. ✓ In 60%, pattern changes into childhood pattern.	❖Dry, leathery and extremely itchy plaques. ❖Mainly on the elbow and knee flexor. Often a reversed (extensor) pattern seen.	❖Intense itchy, lichenified plaques. ❖Cubital and popliteal fossae and sometimes the neck. ❖A low-grade involvement may be seen on rest of the body

Etiology and pathogenesis

➢Genetic factors
➢Skin barrier dysfunction
➢Environmental factors
➢Weak immune system

Diagnostic Criteria

The Hanifin and Rajka'scriteriaare often used:

Major criteria (at least 3 required):

• Pruritus.
• Typical distribution and morphology.
• Chronic or relapsing course.
• Personal or family history of atopy (Asthma, allergic rhinitis or atopic dermatitis).

Minor criteria (at least 3 or 4 required):

• Xerosis (dry skin).
• Ichthyosis or keratosis pilaris.
• Immediate hypersensitivity reactions.
• Hand or foot eczema.
• Elevated serum IgE.
• Early age of onset etc.

Case report

A diagnosed case of atopic dermatitis (AD), 35 years old female patient visited to the OPD of R B T S Govt. Homoeopathic medical college and hospital, Muzaffarpur, Bihar on 2024. Chief complaints are burning, redness as well as itching over the both hand and neck area. Skin is eruptions and itching since last 2 months. All skin complaints aggravated by night time and Amelioration by >scratching after. Patient was diagnosed with atrophic dermatitis by local dermatologist. He prescribed allopathic medicines for similar complaints for last 5 months back. Allopathic medicines are anti fungal, anti histamine as well as steroid local application etc., past history History of recurrent skin eruptions and dryness since childhood. Patient mind is Anger++ (Shouts at her children even shouts on her husband and elders) and deams of dead person. Sleep disturbed due to itching and perspiration mostly in summer but non offensive. Desire for salt and patient thermally towards chilly. Urine clear and has no peculiar odor and stool soft, bowel regular. Appetite- 3meal/day and Thirst- Normal, 3 Litre/day.

Skin Examination:

Skin is dry, persistent dryness of portion of skit unaffected by dermatitis, red skin. Multiple inflammatory eruptions both hand (cubital fossae) and neck region (chin). All skin complaints aggravated by night. Amelioration by >scratching after.

Systemic examination: CVS: S1 and S2 normal, Respiratory system: B/L air entry +, CVS: No abnormality, CNS: Nothing Abnormality defected, Per abdominal: Soft and no organomeglay.

Totality of symptoms

1. Anger (Shouts at her children even shouts on her husband and elders)
2. Desire for salt
3. Thermal reaction-towards chilly
4. Sleep disturb due to itching.
5. Dream of dead person
6. Itching skin eruption < night >scratching after
7. Burning after scratching.

Case analysis (repertorization)

After analyzing the totality of symptoms, the physical and mental, particulars were considered for framing the totality of symptoms. The case was repertorised with the help of homoeopathy software (repertory used-Radar 10.5).

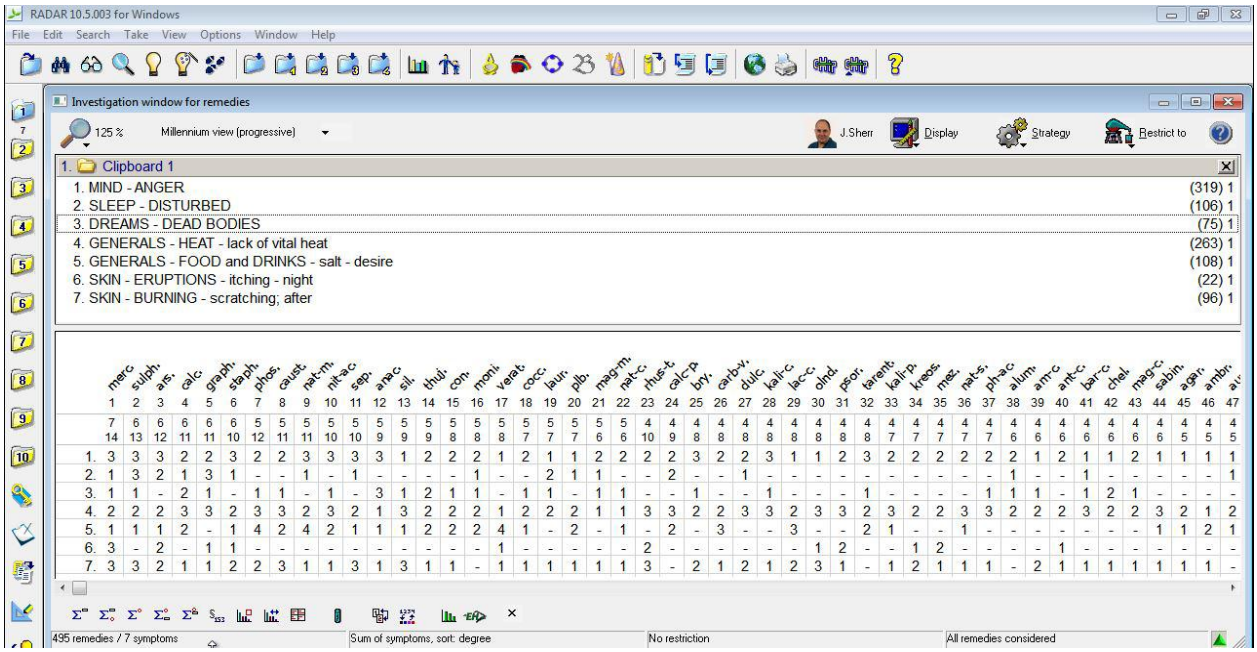

1. Merc sol-14/7, 2. Sulphur- 13/6, 3. Arsenic alb-12/6, 4. Calc carb-11/6, 5. Graphites-11/6

Repertorial analysis and remedy selection

After repertorization Merc sol. got the highest marks. After analysis the totality of symptoms together with Materia Medica I got to conclude that Merc sol. will be the most similimum for this case.

Justification

Why not Sulphur and why Merc sol

- Itching < at night, covered by merc sol but not covered under Sulphur.
- Merc sol thermally chilly (acute) but Sulphur is hot remedy.

Diagnosis

Atopic dermatitis (AD)

Prescription

24.12.024- Merc sol 30/ 6 Doses

Rubrum 200/1dr x BD

Follow up

DATE	SYMPTOMS	REMEDY
08/01/2025	Itchy skin eruptions slightly reduced	Rubrum 200/1dr /bd x 4glob
20/01/2025	Itchy skin eruptions – no further improvement since last prescription	Merc sol 200/2dodes/OD X 4 Glob Rubrum 200/ 1dr/BD X 4 Glob
01/02/2025	Intensity of itching much reduced, and eruption disappeared	Rubrum 200/1dr/ 4glob x BD
13/02/2025	No itching, no eruption, Patient feel better. No new complains	Rubrum 200/1dm/ 4glob x BD
08/01/2025	No itching, no eruption, Patient feel better. No new complains	Rubrum 200/1dm/ 4glob x BD Placebo 200/1 dm/ 4glob x BD

Figure- *Before and after treatment*

Discussion

Homoeopathy is an arrangement of therapeutics which treats the patient not the disease. It additionally focuses on rapid, gentle and permanent reclamation of health. In this case report Merc sol homoeopathic medicine was chosen based on individualization and this medicine was fruitful in the treatment of Atrophic Dermatitis as well as reduced the associated complaints of the patient. After Repertorization numerous medicines were competing with particular Sulphur, Arsenic alb, calc carb, graphites etc., but after conference with Materia Medica Merc sol with ensuring higher potencies from 30 C to 200 was recommended according to reaction of medicine which follows homoeopathy. The standard principal of Initial better on dermatological and psychical symptoms were found viable with treatment by Merc sol 30 and afterward improvement was reduced and the condition became stop. After that, Merc sol with increasing potency (200) was given. The patient improved in all aspects and she did not complaint for any side effects or negative consequences. After 3 months of this homoeopathy prescription, stable improvement was found in Atrophic

dermatitis and associated complaints and also complete remission was achieved in all domains. Treatment and follow-ups with responded with Merc sol.

Conclusion

Homoeopathy system of medicine is a safe, without side effects from of the management with more effects. This case report of Atrophic dermatitis with association complaints that managed to individualized homoeopathic treatment with Merc sol. Homoeopathy might be a useful new treatment methodology for Atrophic dermatitis and further investigations and clinical preliminaries are needed to set up whether it might be efficacious in the treatment of this disorder.

References

[1] Khanna N. *Illustrated synopsis of dermatology & sexually transmitted diseases*. 2nd ed. New Delhi: Elsevier Health Sciences; 2023.

[2] Munjal YP, Sharma SK, editors. *API textbook of medicine*. 10th ed. 2 vols. New Delhi: JP Medical Ltd; 2012.

[3] Colledge NR, Walker BR, Ralston SH, editors. *Davidson's principles and practice of medicine*. 22nd ed. Edinburgh: Elsevier; 2014.

[4] Jamadade AK, Adi BS. Atopic dermatitis with homoeopathic medicine Graphites: a case report. *Int J Altern Complement Med*. 2020; 6(2):21-25.

[5] Allen HC. *Keynotes and characteristics with comparisons of some of the leading remedies of the materia medica with bowel nosodes*. New Delhi: B. Jain Publishers; 2002.

[6] Boericke W. *New manual of homoeopathic materia medica and repertory*. New Delhi: B. Jain Publishers; 2002.

[7] Schroyens F, editor. *Synthesis: repertorium homeopathicum syntheticum*. 9th ed. London: Homeopathic Book Publishers; 2004.